

Intracapsular fractures of the femoral neck Per- and intertrochanteric hip fractures

Alan Norrish, Zaid Abual-Rub

How to use this handout?

The left column is the information as given during the lecture. Personal notes can be made in the right column.

Learning outcomes

At the end of this lecture you will be able to:

- Discuss the importance of blood supply of hip fractures.
- Explain the importance of good positioning, reduction and sterility.
- Describe the implant choice and the procedure step-by-step.
- Suggest how complications can be avoided.

Aim of treatment

The aim of treatment in **younger** patients (<65y) is

- Anatomic reduction and stable internal fixation
- Preservation of femoral head, avoid osteonecrosis, and achieve union
- Ideally avoid arthroplasty
- Maximize potential for return to prefracture mobility



The aim of treatment in **elderly** patients (>65y) is

- Allow immediate weight bearing
- Restore prefracture mobility status
- Avoid prolonged bed rest complications



Hip fractures

1. High energy (rare)
 - Young patients, polytrauma

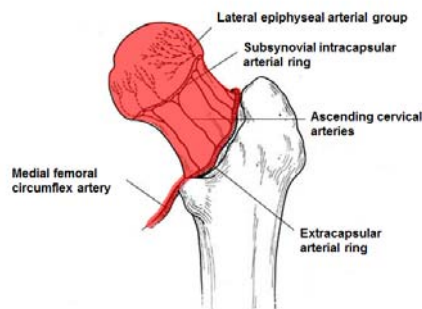


2. Low energy (very common)
 - 15% of women and 5% of men
 - Osteoporosis most common cause
 - Costs **billions** every year
 - Mortality:
 - 10% at 1 month
 - 30% at 1 year

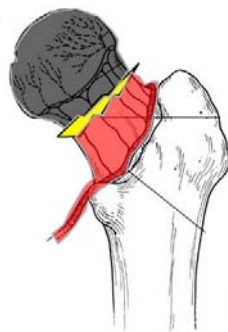


Blood supply

The blood supply to the femoral head comes up from the circumflex artery.



In transcervical fractures the blood supply is at risk, with femoral head necrosis as possible consequence.



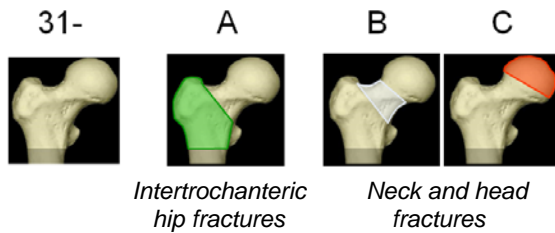
Fracture classification

Will be discussed are

- the AO/OTA Fracture and dislocation classification
- Garden's classification

AO/OTA Fracture and dislocation classification

The proximal femoral fractures are classified as 31 fractures.

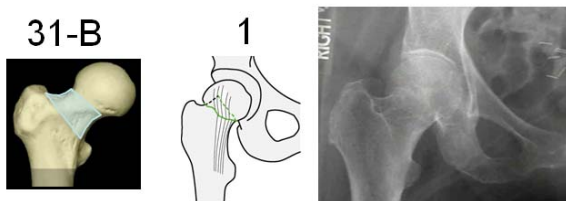


Examples of treatment

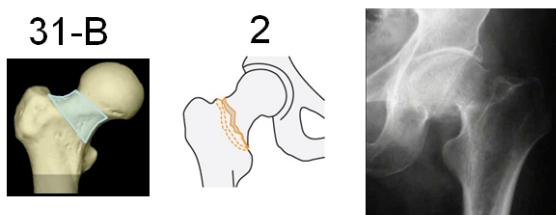
- 31-A with DHS
- 31-B and C with hemi-arthroplasty

We will further discuss the 31-B fractures. The age and physiological status of patients dictate the treatment.

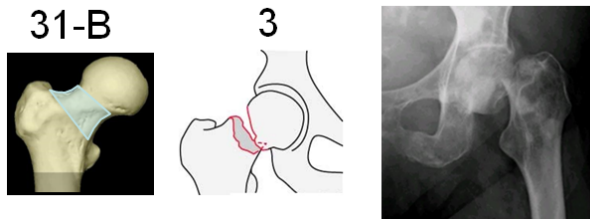
1. The **31-B1** fracture is a subcapital fracture with slight or no displacement. This is a stable fracture which does not always require operative fracture fixation in ambulatory patients or patients with high anaesthetic risk. Operative treatment is indicated in young active patients, unwilling to accept risk of fracture displacement.



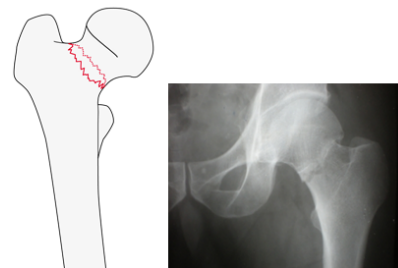
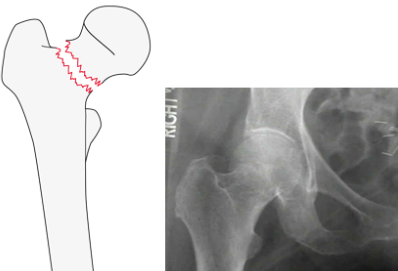
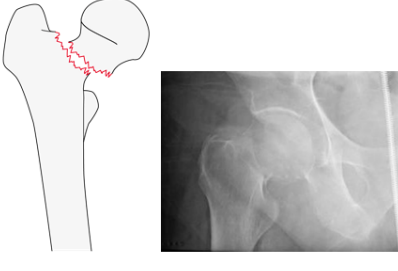
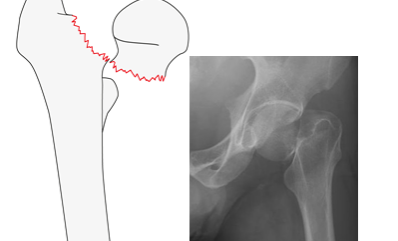
2. The **31-B2** fracture is a transcervical fracture with some displacement. This is an unstable fracture which will be reduced open or closed and is treated with a dynamic hip screw, cancellous bone screws or arthroplasty.



- The **31-B3** fracture is a subcapital displaced fracture. First open or closed reduction is performed. When the bone quality is good, the fracture can be fixed with cannulated bone screws. Osteoporosis is an indication for the use of a dynamic hip screw. Advanced age and irreducible fractures are indications for arthroplasty.

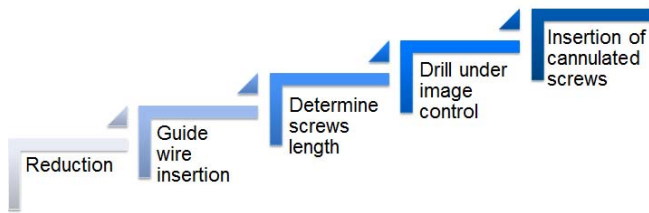


Garden's classification

- The **type 1** fracture is an undisplaced incomplete fracture. It also includes valgus impacted fractures.
 
- The **type 2** fracture is an undisplaced complete fracture.
 
- The **type 3** fracture is a complete fracture, incompletely displaced.
 
- The **type 4** fracture is a complete fracture, completely displaced.
 

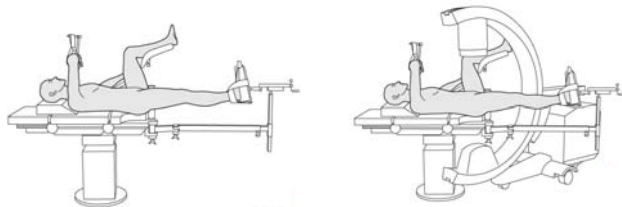
Cannulated cancellous screws

Technique



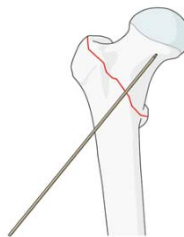
Step 1—reduction

In many cases closed reduction is done by using the traction table. The patient is draped once the reduction is performed. Before draping it is also important to guarantee smooth access of the image intensifier in both planes; AP and lateral.

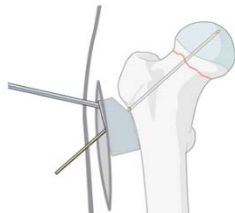


Step 2—guide wire insertion

1. The anteversion of the femoral neck is determined with a long K-wire inserted with the blunt end first. An alternative is to use a long, non threaded K-wire.



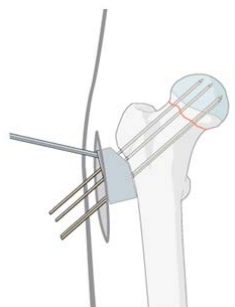
2. Preliminary fracture fixation is performed with a guide. The guide wire is drilled parallel to the anteversion wire through the central hole of the aiming device. The position of the guide wire is controlled with the image intensifier.



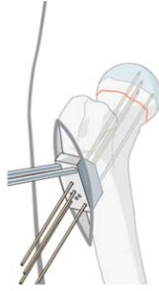
Step 3—screw length

1. Insertion of three guide wires into the head:

- Position the aiming device so that at least one of the caudal screws will rest on the calcar.
- Wires should be just short of the subchondral bone.

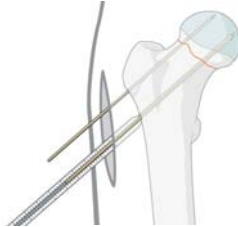


- Remove the central guide wire and the aiming device.
- Check position of wires with the c-arm.



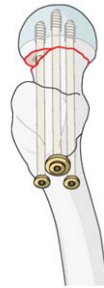2. Measuring of screw length with depth gauge:

- The length of the drill and screws is 5 mm shorter than the length of the guide wires.

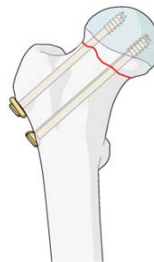


Step 4—drilling

1. Drill over the wires with a 3.6 mm cannulated drill bit.
2. Insert three 7.0 mm or 7.3 mm cannulated cancellous screws over the wires.



3. In younger patients with dense cancellous bone, the cannulated tap may be necessary to precut the thread.
4. Use washers to avoid penetration of the screw heads through the thin cortex.



Complications

Femoral neck non-union and AVN are the two most significant long-term complications following ORIF.

Factors associated with increased incidence of complications:

1. Increased initial displacement
2. Nonanatomical reduction of fracture

Arthroplasty

Indications

- Displaced intracapsular femoral neck fractures
- Age > 65

Total hip replacement

- Preexisting acetabular disease
- Factors influencing the treatment:
 - Patients who were able to walk outdoors with no more than stick
 - Not cognitively impaired
 - Medically fit for anaesthesia and procedure

Take-home message

- For intertrochanteric fractures, good blood supply allows fixation rather than replacement.
- The procedure starts with positioning and a closed reduction (maintain sterile field).
- The right implant must be selected for each fracture type (DHS, PFNA, and long PFNA).
- Good instruments can be laid out to facilitate a step-by-step approach to each procedure.
- Preoperative planning reduces complications.

Summary

You should now be able to

- Discuss the importance of blood supply of hip fractures.
- Explain the importance of good positioning, reduction and sterility.
- Describe the implant choice and the procedure step-by-step.
- Suggest how complications can be avoided.

Questions

1. Sum up the complications of internal fixation with cannulated cancellous bone screws.
2. What are the indications for total hip replacement?
3. Which factor is strongly related to non-union in femoral neck fractures?

Reflect on your own experiences

- Do you know the correct steps of procedure for fracture fixation with cannulated cancellous bone screws? What are the correct sizes of instruments?
- What would you take out this lecture and transfer into your practice?

Notes