

Implant removal

Bruce Twaddle

How to use this handout?

The left column is the information as given during the lecture. The column at the right gives you space to make personal notes.



Learning outcomes

At the end of this lecture you will be able to:

- Outline the role of ORP in planning for implant removal
- Discuss what is required to remove broken and damaged implants

Implant removal is an operation that is never associated with the concept of "success". It is often left to the more junior members of a surgical team, at the end of the list, when many of the experienced medical and ORP staff have already left. This procedure, therefore, has the highest incidence of minor, and sometimes serious, complications of any that we perform and can often result in a more prolonged period of recuperation for the patient than anticipated. It is important to realize that implant removal is certainly not easy and all members of the surgical team should be prepared for a number of unforeseen incidences, have available the appropriate equipment and all information referring to the implanted device(s).



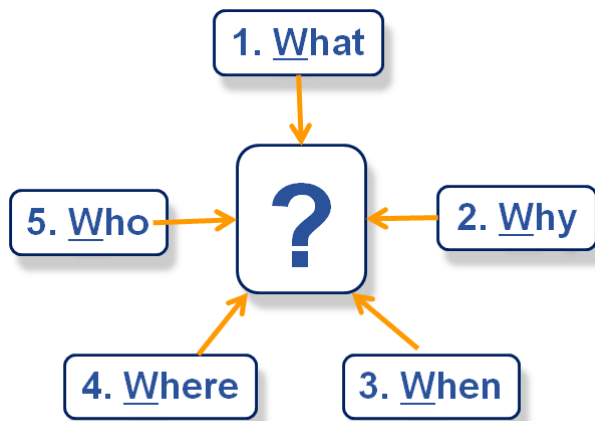
It has been said that implants are like fish-hooks: they are easier to put in than to take out!

Planning for implant removal

Never underestimate implant removal. It requires meticulous planning and communication

"Failing to plan is planning to fail"
Benjamin Franklin

Rule of W's

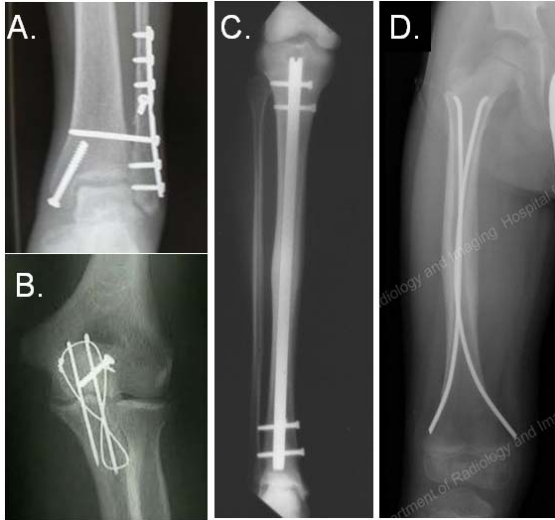


Rule of W's or five questions will help with the preparation for implant removal surgery:

1. What needs to be removed? Which implants have to be removed?
2. Why does the implant need removal?
3. When was it implanted?
4. Where is the implant located?
5. Who will do the removal?

1. What needs to be removed?

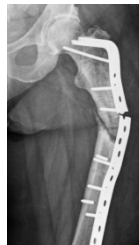This is the first and most obvious question. Here are some examples shown.



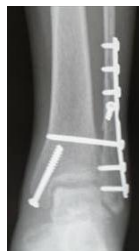- a) Plate and screws
- b) Wires and screws
- c) Nail and bolts
- d) Pediatric nails

There are some fundamental principles that are essential if you are to avoid, not only the embarrassment of not being able to remove the implant, but additional risk to the patient.

- Is the implant broken? Which additional instruments are likely to be needed?



- Are all parts removed which need to be removed?



- Of which material is the implant? (e.g. stainless steel is less brittle and easier to remove than titanium and there is less adhesion)
- Of which make and model is the implant? The extraction set of intramedullary nail depends on the type.
- What is the surgical plan?

With the wide range of trauma implants now available, it is very important to have a very clear idea of what implant is involved and what product it is. For example some IM nail locking screws will have a hexagonal head and some more recently inserted nails will have a star drive head. The precise details of the implant are very important. Corresponding extraction tools will need to be made available before scheduling the patient for surgery.

2. Why does the implant need removal?

A. After consolidation of the fracture

Here are some recommended guidelines:

- Wires and screws should be removed at 3 months
- Plates of long bones should be removed at 18 months
- Periarticular plates should also be removed at 18 months
- Intramedullary implants (eg, nails) should also be removed at 18 months

These are guidelines for removal after a normal fracture healing process. Ideally an implant should not be removed before the fracture is solidly united and the implant is no longer serving any purpose.

Different countries, regions, hospitals have different protocols. Not every implant needs to be removed and every country has different legal, cultural, and perceptual influences that dictate if an implant should be taken out. In some countries the law or custom makes implant removal almost mandatory.

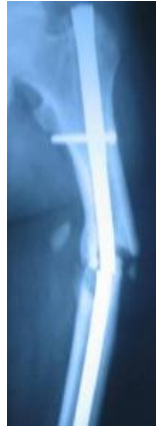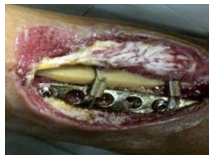If the implant, by being subcutaneous or irritating some other structure, is causing the patient symptomatic disability then it is beneficial to try to remove it, provided the fracture has united.

Theoretically routine removal is usually straight forward, but remember do not underestimate any implant removal!

B. Before consolidation of the fracture

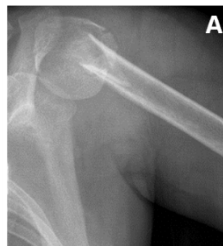If the implant, and usually the fracture that it was fixing, has obviously failed, then in the majority of cases, unless the condition of the patient dictates otherwise, the implant should be removed and an alternative form of fixation applied.

- 1) Nonunion of fracture
- 2) Breakage of implant
- 3) Joint penetration
- 4) Dynamization of fracture (with nail)
- 5) Pain
- 6) Infection

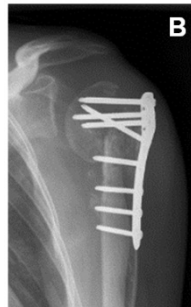

Example 1—Sequential screw removal due to joint penetration

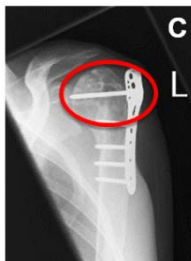This is an example (A) of a fracture of the proximal humerus in a patient with a complex history of anorexia, substance abuse, and drug overdose. The original fracture fixation was complicated by an infection.



The fracture was revised to this construct (B) but, as it collapsed and healed, the fixed angled screws penetrated the joint one by one and had to be removed sequentially, until all the screws in the proximal portion of this locking plate were removed.

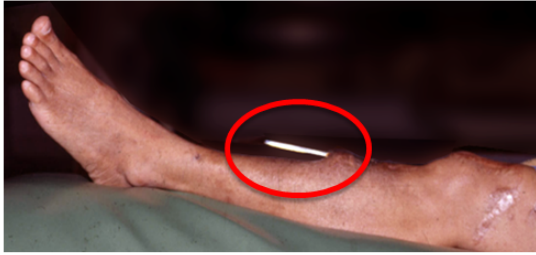

The picture on the right shows the last screw having penetrated the joint (C). Fortunately the fracture united without avascular necrosis (AVN) and because of vigilance and anticipation of this problem, a satisfactory result was achieved, considering the complexity of the case.



Example 2—Protruding implant

A protruding implant that obviously needs to be removed!



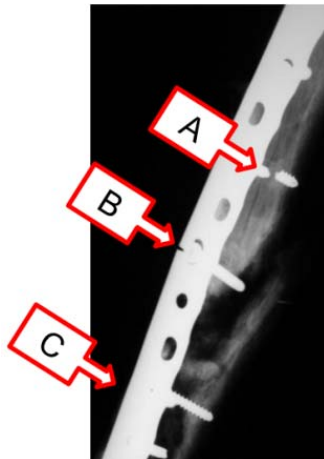
Courtesy of [S Bavonratavech](#)

Example 3—Broken implants

In this case, the fracture did not unite and the repeated stresses on the plate and screws have resulted in fatigue failures.

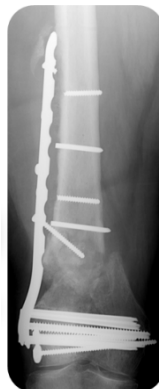Plate failure—fatigue

- Broken screws (A and C)
- Broken plate (B)



Example 4—Broken implants

Here is an example of a LISS plate with broken LHS.



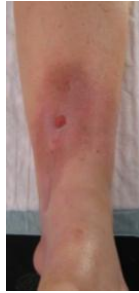What to do when the fracture is infected but not yet healed?

1. The implant stays in situ

Twaddle states that even infected implants can stay intact until bone healing has been achieved.

2. The implant has to be removed

In infected fixations, if the implant is no longer providing stability, its removal will be part of the treatment program. The implant has to be removed when the infection is deep and severe.



Procedure

Step 1—Try to keep the implant in situ until union for as long as it stabilizes the fracture.

Treat the infection with debridement, local and general antibiotics.

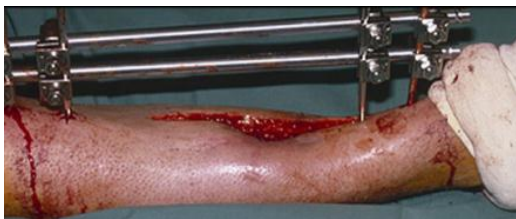Step 2—Infection is very severe and deep. Implant is unstable.

Implant must be removed. Consider temporary splintage. Alternative stabilization, often an external fixation. Treat the infection with debridement, local and general antibiotics.

ORP preparations for removal

ORP considerations will be derived from the surgical plan.

- Is all correct equipment available? Is the broken implant removal set available in case this is needed? Screws can also break while removing.
- In case of implant failure, will there be an alternative fixation?



- Are bone grafts an option?
- Was there a previous infection? This may determine the need for microbiological studies of tissue biopsies to check for any continuing infection.
- In case there is an infection:
 - What is needed for debridement and lavage?
 - Are local antibiotics required?
 - Are special dressings available? VAC dressings?
 - Is specimen collection needed?

Important also is improvisation.

3. When was the implant inserted?

The longer an implant has been in place, the more difficult it may be to remove.

Reasons can be:

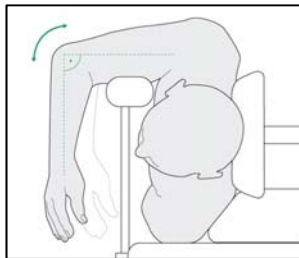
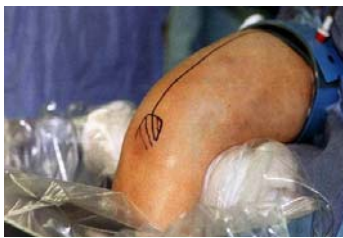- Ingrowth of tissues in threads of implant
- Connective tissues on smooth implant surfaces
- Severe corrosion
- Titanium implants may be more difficult to remove

Search always for the date of implantation before the start of the implant removal.

4. Where is the implant located?

The location of the implant will define the position of the patient.

In this example a rarely used position was needed for the implant removal in a humeral shaft fracture—with a posterior approach.



5. Who will do the removal?

Is the team experienced with the technique? Rules are

- The insertion and extraction techniques must be known by the entire team.
- The surgeon who implanted it should remove it. He/she knows exactly how it has been implanted and if there were any difficulties, closely related anatomical structures, etc. However, this is not always possible.
- It is also important to know in advance whom to contact for help should you have a problem.

How to get all the information?

1. Communication—Find out the surgical plan.
2. X-rays—It is essential to have recent x-rays of the affected bone and implant in case something may have changed in the interim. A common example of this is when a diastasis screw for an ankle fracture is to be removed and it has broken since the patient was last x-rayed.

Make sure to have always

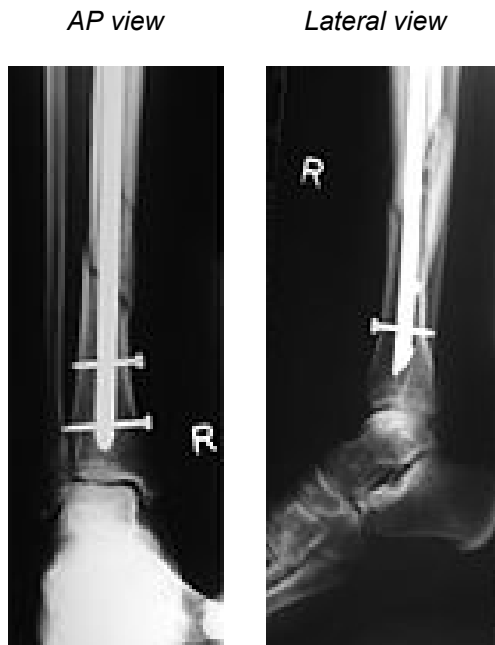- recent x-rays present (as they might show implant breakage, etc)
- AP and lateral views present

With the x-rays you can

- Count the implants
- Define the size of the implants
- Assess for breaks and damage

Example 5—Removal of locking bolts

The next x-rays show that if the surgical planning is based on the AP view only we might think that only two distal bolts must be removed. The lateral view, however shows that a third bolt must be removed before the nail can be extracted.



Difficult implant removal

In this section difficult removal of broken screws, intramedullary nails and pediatric implants will be discussed.

1. Removal of broken screws

There may be no information prior to surgery that broken screws need to be removed.

When broken screws are present, the set for removal of broken screws should be prepared before the operation starts. The picture shows an example of such a set.



The set contains many different items. It is extremely important that the scrub-nurse and the surgeon both know exactly which instrument is used and for what purpose.


Damage of screw might have happened during

- Insertion
- The healing process
- Removal

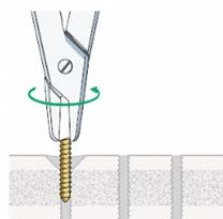
a) Shallow seated screw shaft (or sheared head)

Removal procedure:

1. First enlarge access to screw shaft with a gouge.



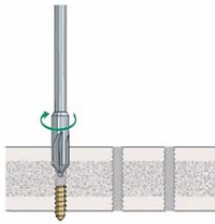
2. Try to remove the shaft anticlockwise with pliers. If the screw shaft is not sufficiently exposed the conical extraction bolt can be used. This is explained in the next later.




b) Deep seated screw shaft

Removal procedure:

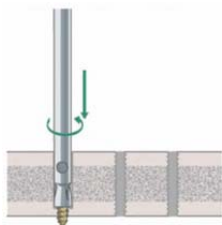
1. First use a countersink clockwise to enlarge the screw hole and get good access to the screw shaft.



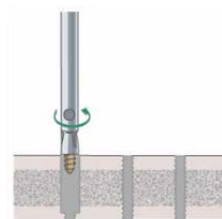
2. Drill anticlockwise around the shaft using a hollow reamer, which is assembled with its centering pin. Take care to select the correct reamer size! Assembling the reamer may seem difficult as it is all reversed thread. ORP must try this out before surgery.



3. Insert the correct size extraction bolt counterclockwise.



4. Remove the shaft fragment.



c) Screw with stripped recess

Stripping the recess can in many cases be avoided when

- The screw is inserted manually (final tightening)
- The screw is inserted with a torque limiter for the insertion of LHS
- The screw is loosened manually
- The correct screwdriver is used
- A standard screwdriver is used for removal



The most common problem with implant removal is the screwdriver type and size. ORP should make every effort to ensure that they have the correct instruments.



A screwdriver's name is closely related to the shaft of the screw it is designed to insert and remove. For example a small fragment screwdriver is named 2.5 mm screwdriver.

Important note on LHS

- Insertion of LHS is always done with a torque limiter.



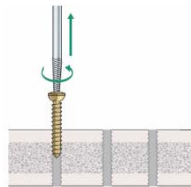
There are different types of torque limiters. Make sure you have the correct screwdriver for the particular screw type you are inserting.

- Extraction of LHS is always done with a standard screwdriver. A torque limiter is a very expensive tool and is not a necessary instrument for the extraction.



Removal procedure:

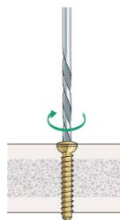
1. Try to insert the conical extraction screw counterclockwise and remove screw.




The conical extraction bolt is assembled onto a T-handle. Note that there are 2 sizes available.



2. Destroy the screw recess with a (larger) high speed drill bit.



This photograph shows how much metal debris is produced when drilling out the screw recess to separate the head. Be sure to irrigate copiously with cold Ringer-lactate solution throughout drilling.



d) Jammed locking head screws (LHS)

Seldom do all LHS come out easily.

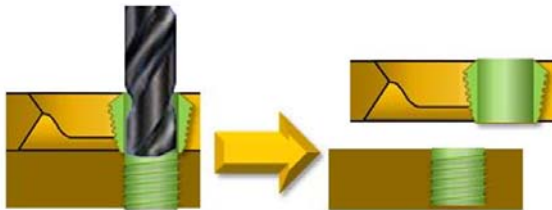
The problems are:

- Cross threading—screw was not inserted correctly (which should have been perpendicular to the LCP). Oblique insertion and mismatch of threads took place during insertion. Hence the importance of the correct use of the appropriate drill sleeve by insertion.
- Cold welding—The thread of the screw head becomes cold-welded (fused) with the thread of the plate hole
- Stripped screw head recess—The recess in the head of the screw can easily be stripped when screw removal is difficult. The material (titanium is softer) will play an important role.

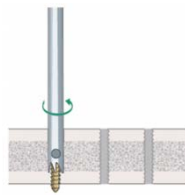


Removal procedure:

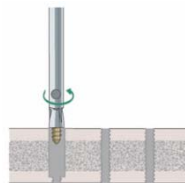
1. Use a high-speed, hardened drill bit to detach screw from plate



2. Attach hollow reamer to screw shaft (*same procedure as conventional screws*)



3. Remove screw with extraction bolt (*same procedure as conventional screws*)



DIY-kit (Do it yourself kit)

Use for removal of broken screws always special instruments:

- A sharp hook
- The best screwdrivers



- The worst osteotomes/gouges
- Different pliers
- Old needle holder
- ...

A special set with instruments for implant removal only can be created.

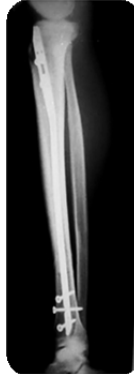2. Removal of intra medullary nails

Problems:

- Interlocking screws are broken
- Recess of screws/nail is damaged

Procedure for normal removal of IMN:

- Have correct instruments available. This is only possible when you know which implant will be removed.
- Removal starts with good access
 - Interlocking screws are removed (The screw is called an interlocking screw to distinguish from locking head screws.)
 - Nail is removed—soft-tissue and bony overgrowth must be completely removed from the top of the nail.



As mentioned before improvisation is important when removal of broken implants, certainly when an IMN is in place.

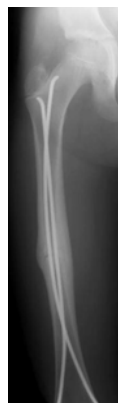
When removal of intra medullary nails in pediatric patients, special care is needed as the growth plates are still open.

Problem:

- Overgrowth of bone

Procedure:

- Use of special pliers



Summary

You should now be able to:

- Outline the role of ORP in planning for implant removal
- Discuss what is required to remove broken and damaged implants

Questions

1. Which instrument(s) is(are) used for removal of a screw shaft which remained in the bone?
2. Which instrument do you always use for the removal of a LHS?
3. Which standard procedure is followed when the implant(s) is(are) infected?

Reflect on your own experiences

- What are the protocols in your hospital?
- Which procedure is followed in your hospital, when the implant(s) is/are infected?
- Do you have a DYI (Do It Yourself) kit? If so, does it contain other instruments? If not, would you suggest this in your OR?
- What would you take out this lecture and transfer into your practice?

Notes