

## Proximal femoral fractures

### Per- and intertrochanteric hip fractures

Alan Norrish

#### How to use this handout?

The left column is the information as given during the lecture. The column at the right gives you space to make personal notes.

#### Learning outcomes

At the end of this lecture you will be able to:

- Discuss the importance of blood supply for hip fractures
- Explain the importance of positioning, reduction, and perioperative sterility
- Describe the implant choice and the procedure step-by-step
- Suggest how complications can be avoided

#### Aim of treatment

The aim of the treatment is

- Stable fixation that **always** allows immediate weight bearing
- Minimize potential for implant failure
- Maximize potential for return to prefracture mobility



#### Hip fractures

Hip fractures are

##### 1. High-energy fractures

These less common fractures are often caused by road accidents. The patients are often young with multiple traumata.



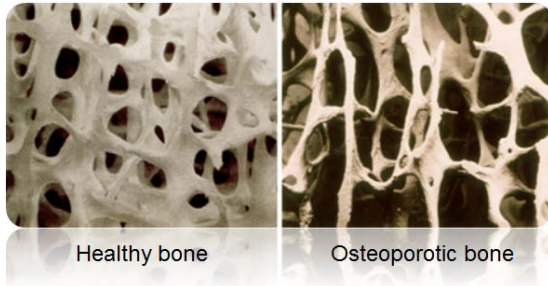
##### 2. Low-energy fractures

15% of women and 5% of men will sustain this type of fracture which is mainly due to osteoporosis. The treatment of these fractures costs the health sector billions each year and they have a mortality of 10% at one month and 30% at one year.

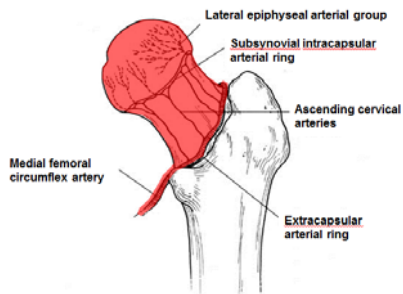


## Osteoporosis

Osteoporosis or reduced bone mineral density is common with aging and can lead to “fragility fractures”.

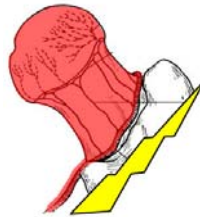


## Blood supply

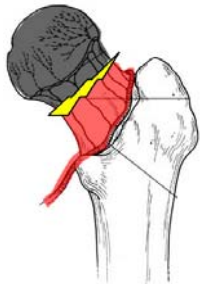

The blood supply to the femoral head comes up from the circumflex artery.

In intertrochanteric femoral fractures the femoral head blood supply is preserved and the fracture can be fixed.

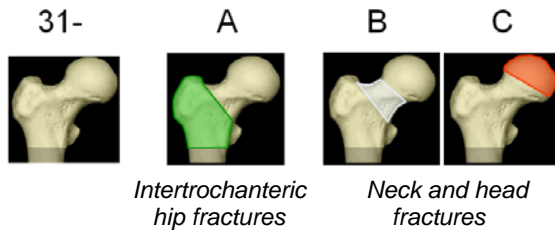


When transcervical fractures the blood supply is at risk with necrosis of the femoral head as consequence. The surgical treatment will be hemiarthroplasty or head replacement.



## Fracture classification

The proximal femoral fractures are classified as 31 fractures.

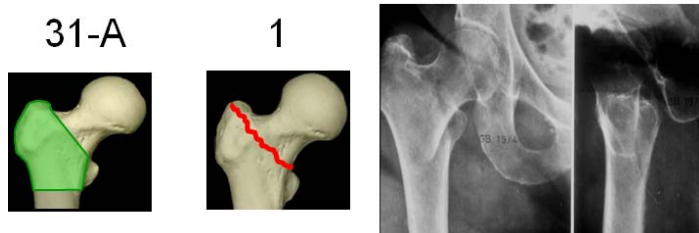


Examples of treatment

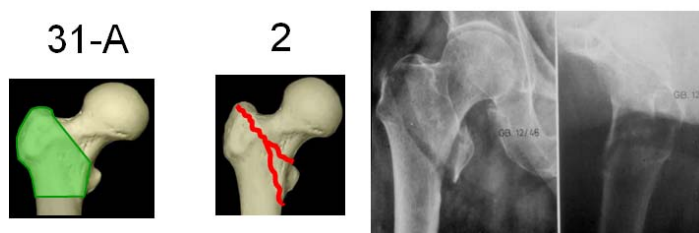
- 31-A with DHS
- 31-B and C with hemiarthroplasty

We will further discuss the 31-A fractures. There are several subtypes of fractures which require different treatments and different implants for fixation.

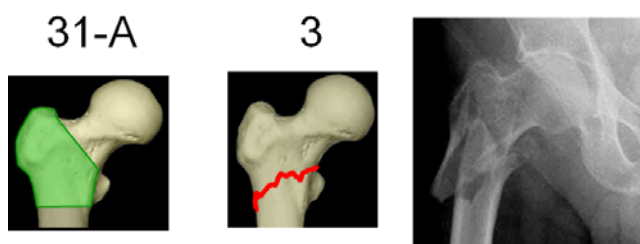
1. The **31-A1** fracture is a simple stable trochanteric fracture and requires a DHS (Dynamic Hip Screw) as treatment.



2. The **31-A2** fracture is a comminuted unstable trochanteric fracture and requires a DHS or a PFNA (Proximal Femoral Nail Antirotation) as treatment.



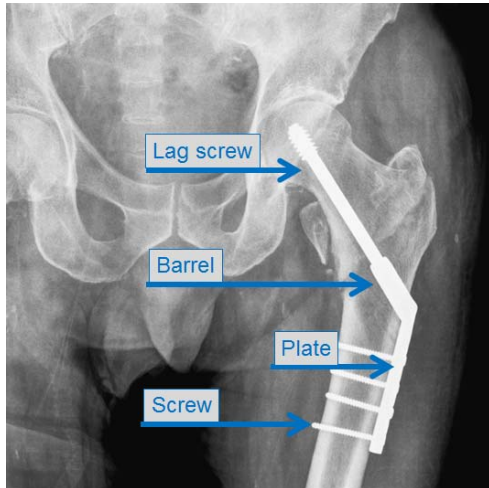
3. The **31-A3** fracture is a reverse oblique (stable or unstable) trochanteric fracture and requires a PFNA as treatment.



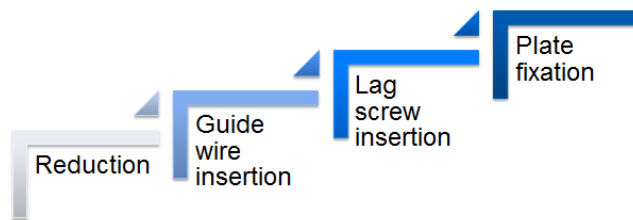
## Dynamic Hip Screw (DHS)

### Design

The DHS implant consists of a lag screw and a plate with a barrel in which the lag screw can glide. The plate is fixed with standard 4.5 mm screws.

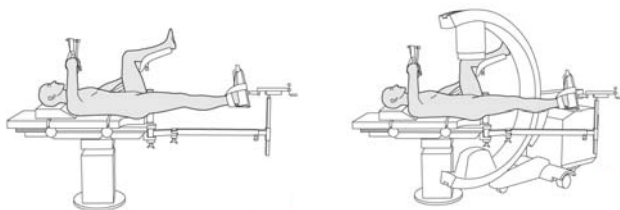


### Technique



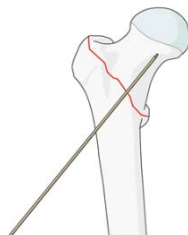
#### Step 1—reduction

In many cases the traction table is used. The reduction is done on this table and before the patient is draped. Important also is to guarantee smooth access of the image intensifier in both planes; AP and lateral.

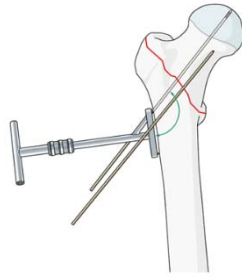


#### Step 2—guide wire insertion

1. The anteversion of the femoral neck is determined with a long K-wire inserted with the blunt end first. An alternative is to use a long, nonthreaded K-wire.

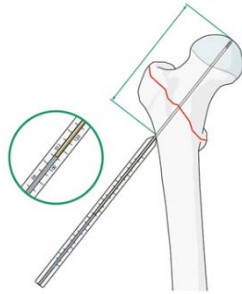


- Under X-ray control, the guide wire is inserted parallel to the anteversion wire by using the 135° guide fixed on the T-handle.

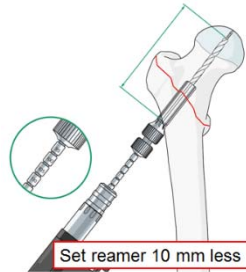


### Step 3—screw insertion

- The length of the screw must be measured/determined with the guide wire. Note that the screw must be 10 mm shorter than the length of the guide wire. The surgeon will deduct 10 mm of the measured length to determine the screw length.



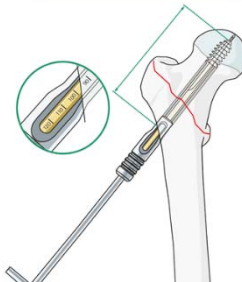
- Set the triple reamer to 10 mm shorter than the measured length. The hole is drilled over the guide wire.



- Tapping is only required in young patients with dense bone.

- The plate is assembled:

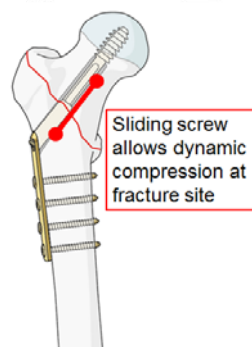
- The coupling screw is inserted into the wrench.
- The plate is slid over the wrench.
- The DHS screw is attached to the coupling wrench.
- The sleeve is assembled over the wrench.



### Step 4—plate fixation

Impact the plate in order to have best contact with the femur. The plate is fixed with conventional 4.5 mm screws:

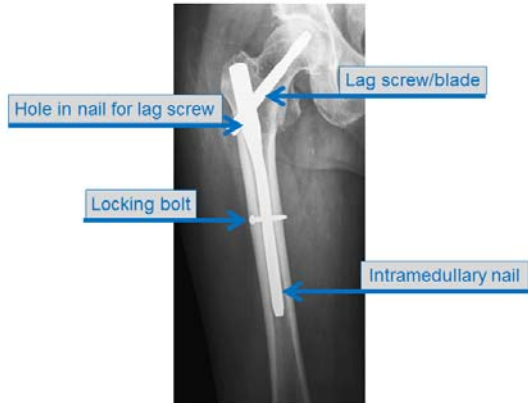
- Drill bit 3.2 mm with sleeve
- Measuring
- Tap (when no self-tapping screws are used)
- Insertion of screw



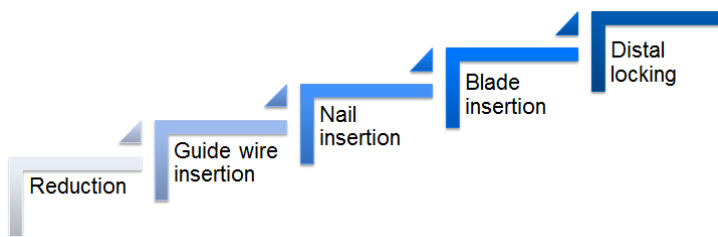
## Proximal Femoral Nail Antirotation (PFNA)

### Design

The PFNA is an intramedullary nail with an antirotation lag screw/blade in the femoral head.



### Technique

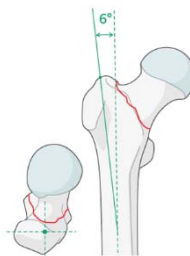


#### Step 1—reduction

The same procedure as for DHS is followed.

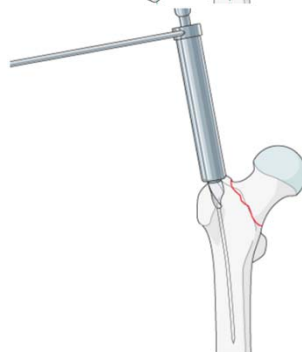
#### Step 2—guide wire insertion

The entry point is in line with the central axis of the femoral neck. The guide wire is inserted through the tip of the greater trochanter in the femoral canal. The insertion is done under x-ray control in AP and lateral view.

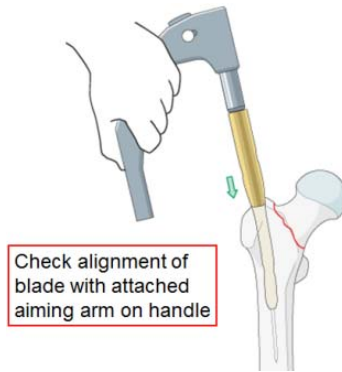


#### Step 3—nail insertion

1. The medullary cavity is opened with the cannulated 17.0 mm drill bit drilling down to its stop.

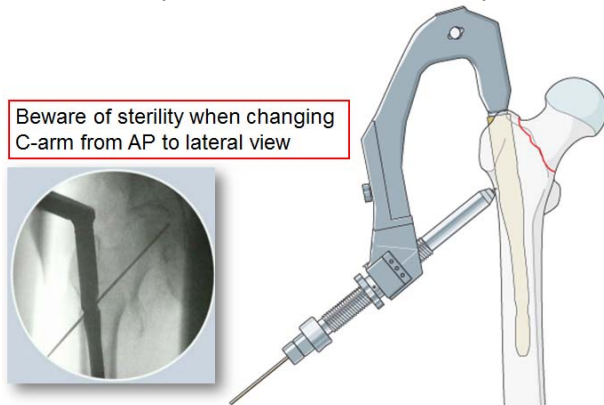


2. Assemble the PFNA onto the insertion handle. Before the nail is handed over to the surgeon, the scrub nurse fixes the aiming arm on the handle and checks with a K-wire (through the locking holes towards the nail) the good functionality of the instruments.

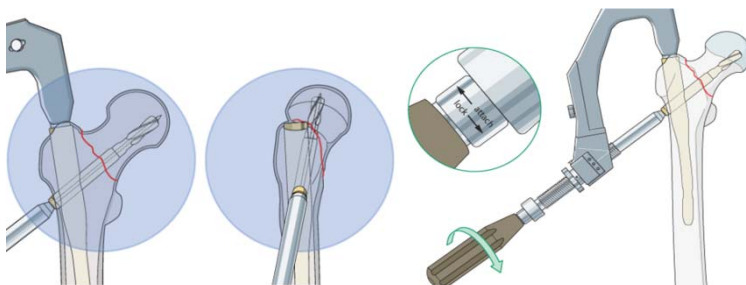


#### Step 4—blade insertion

1. The guide wire is inserted:
  - The protection sleeve is assembled (four parts) and entered in the aiming arm. It is clicked into place and advanced to the lateral cortex by turning the buttress nut.
  - The trocar is removed.
  - The guide wire is inserted in the center of the femoral head. The position is checked in both planes.



2. The blade is inserted:
  - The length of the blade is determined with the direct measuring device.
  - The lateral cortex is opened with the 11mm drill bit (with stop). The 11mm reamer can be used as alternative. In this case the length of the fixation sleeve must be set to the measured length of the helical blade. Reaming is not required in patients with severe osteoporosis.

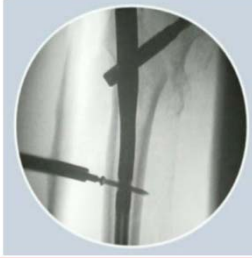

#### Step 5—distal locking

The nail is locked distally:

1. The triple guide is inserted.
2. The trocar is removed.
3. The locking hole is drilled and measured (on drill guide).
4. The inner sleeve is removed.

- The locking bolt is inserted through the outer sleeve.



✓ Correct position is checked in both planes

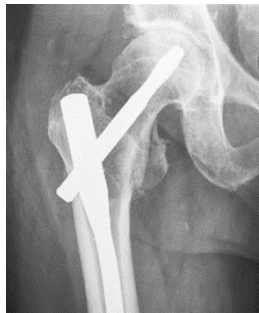## Advantages

- PFNA more stable:
  - For reverse oblique fractures
  - For subtrochanteric fractures

## Complications

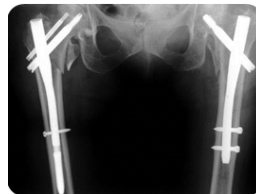
- PFNA less stable
  - In periprosthetic fractures (in some countries; eg, UK, the short PFNA is no longer recommended)

- Wrong position of lag screw leading to cut out syndrome (screws cuts out of femoral head). To avoid this the implant must be correctly positioned:
  - Close to joint
  - In middle of head in both AP and lateral view



- Wrong selection of implant
  - Implant failure (eg, DHS in very unstable fractures can lead to malunion)

- Periprosthetic fracture
  - More common in:
    - Short IM nails than in DHS
    - Nails where distal screw is near tip of the nail

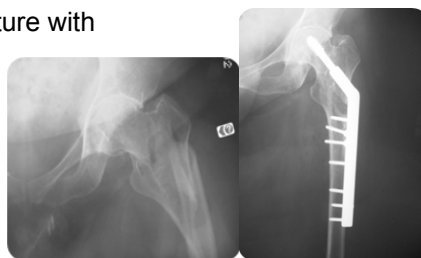


- Infection
  - Sterility is important

## Case

This intertrochanteric fracture with subtrochanteric extension was treated with a DHS.

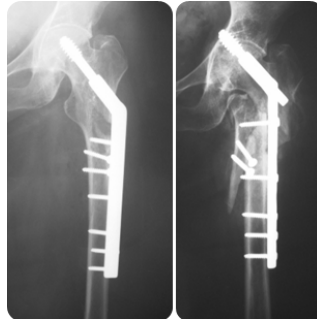
- Is this the best implant?
- What may happen?





**Complications:**

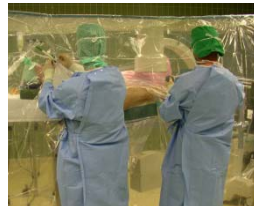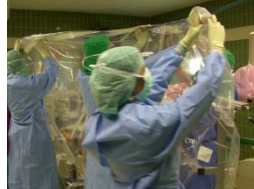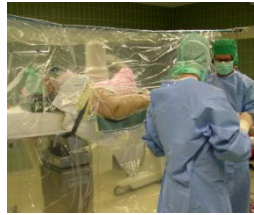- Fixation failed
- Screw cut out
- Leg shortened
- Leg malrotated



## Special considerations for sterility

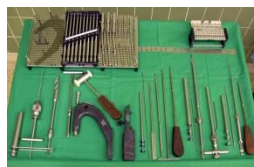**Beware of:**

1. Surgeon's back: Ensure gown is done up tightly as surgeon faces away during whole procedure
2. Transparent isolation drape:
  - Ensure skin is dry or drape peels off
  - Positioning the drape requires the hand to move over the head—not a recommended position, great care must be taken
3. C-arm:
  - Protect drape when turning from AP to lateral view



## Support surgeon

1. Support surgeon to follow the correct procedure.
2. Control completeness of instrument sets.



## Summary

**You should now be able to**

- Discuss the importance of blood supply for hip fractures
- Explain the importance of positioning, reduction, and perioperative sterility
- Describe the implant choice and the procedure step-by-step
- Suggest how complications can be avoided

## Questions

What is the correct answer? More answers can be possible.

**1. The blood supply of proximal femoral fractures is...**

- ... not disturbed much in intertrochanteric fractures
- ...disturbed in transcervical fractures
- ...always result in femoral head necrosis

**2. How do you set the DHS reamer?**

- Set reamer according to correct measurement
- Set reamer 10 mm less than measurement
- Set reamer 10 mm more than measurement

**3. What are, in your opinion, important nursing considerations during an osteosynthesis with DHS or PFNA?**

- Maintaining sterility
- Knowing the procedure step-by-step
- Guaranteeing a smooth change from AP to lateral view with the image intensifier

## Reflect on your own practice

Which content of this lecture will you transfer into your practice?